

Intra-Tracheal Nitinol Stents

New Options for Treating Tracheal Collapse

Brendan McKiernan, DVM, Diplomate ACVIM

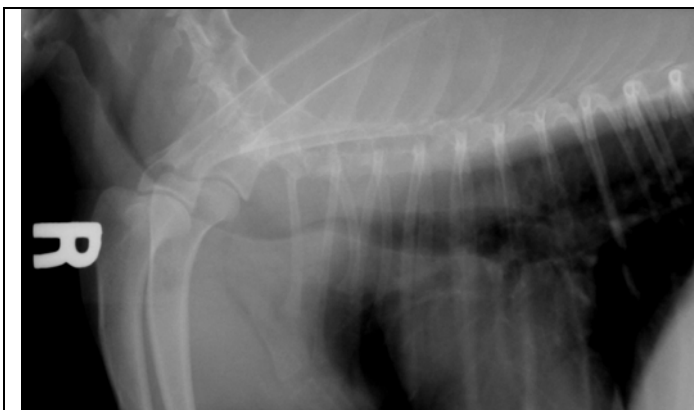
Dynamic tracheal collapse is a common chronic airway disorder, particularly in small breed dogs. Commonly affected breeds include Yorkies, Pomeranians and Poodles. Presenting dogs are commonly younger to middle aged and often overweight.

DIAGNOSIS is made based on signalment, physical findings, thoracic radiographs/fluoroscopy and particularly on bronchoscopy. The latter allows for confirmation of the diagnosis as well as collection of samples for culture and cytology which is important for long term management.

MEDICAL TREATMENT is basically that of chronic bronchitis: weight management, avoidance of trigger situations, antiinflammatories, and in many cases bronchodilators. Antibiotics are usually not indicated as most chronic bronchitis cases are not infectious (there are exceptions of course).

SURGICAL TREATMENT in the past has involved the placement of external plastic rings (the old hand made syringe case rings or the new commercial *New Generation* tracheal rings). External tracheal ring surgery is limited to the cervical and thoracic inlet trachea. Tracheal collapse however often involves the intrathoracic trachea or in severe cases the entire length of the trachea.

About 5 years ago I began to use the **nitinol intraluminal tracheal stent** in severe tracheal collapse cases. Although these stents can be placed under fluoroscopic guidance, this is often not available. I developed a technique for placing these under bronchoscopic guidance and the additional information gained from a complete bronchoscopic evaluation is invaluable. Here is an example of one such case I recently did here at the SOVSC:



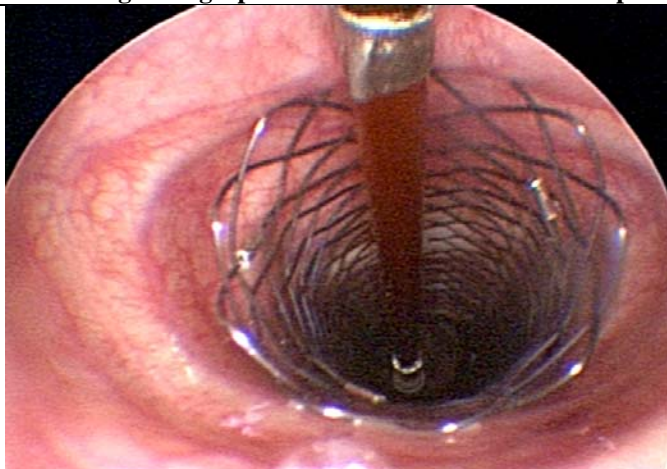
Admitting radiograph - severe cervical tracheal collapse.

Signalment: 3yr FS Pom.

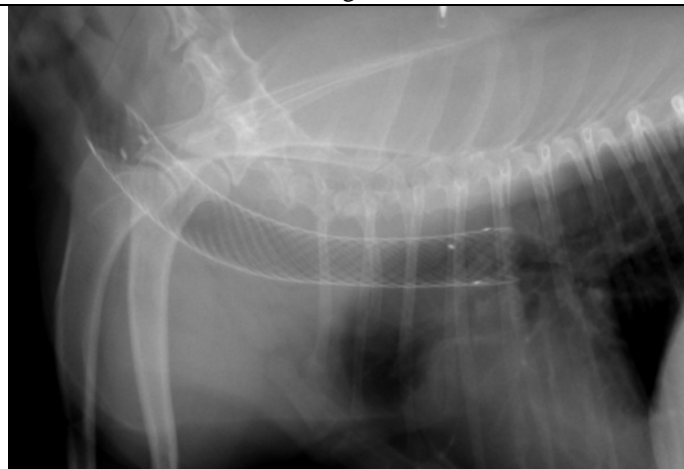
History: "Weird breathing issues", worse with excitement, cyanotic 2 days ago and was intubated. Referral for tracheal collapse.

Physical: BAR, BCS = 7-8/9. MM color initially good but deteriorated with excitement. Inspiratory wheezing (stridor) noted during exertion. Referred for possible tracheal collapse.

Bronchoscopy: The severe cervical collapse was confirmed but the intrathoracic trachea was also abnormal and a decision was made to stent the entire length of the trachea.



Completion of bronchoscopic stent deployment.



Chest radiograph immediate post stent placement.



Southern Oregon
VETERINARY SPECIALTY CENTER

If we can help with any of your cases please don't hesitate to call!

**3265 Biddle Rd.
Medford, OR 541-282-7711**